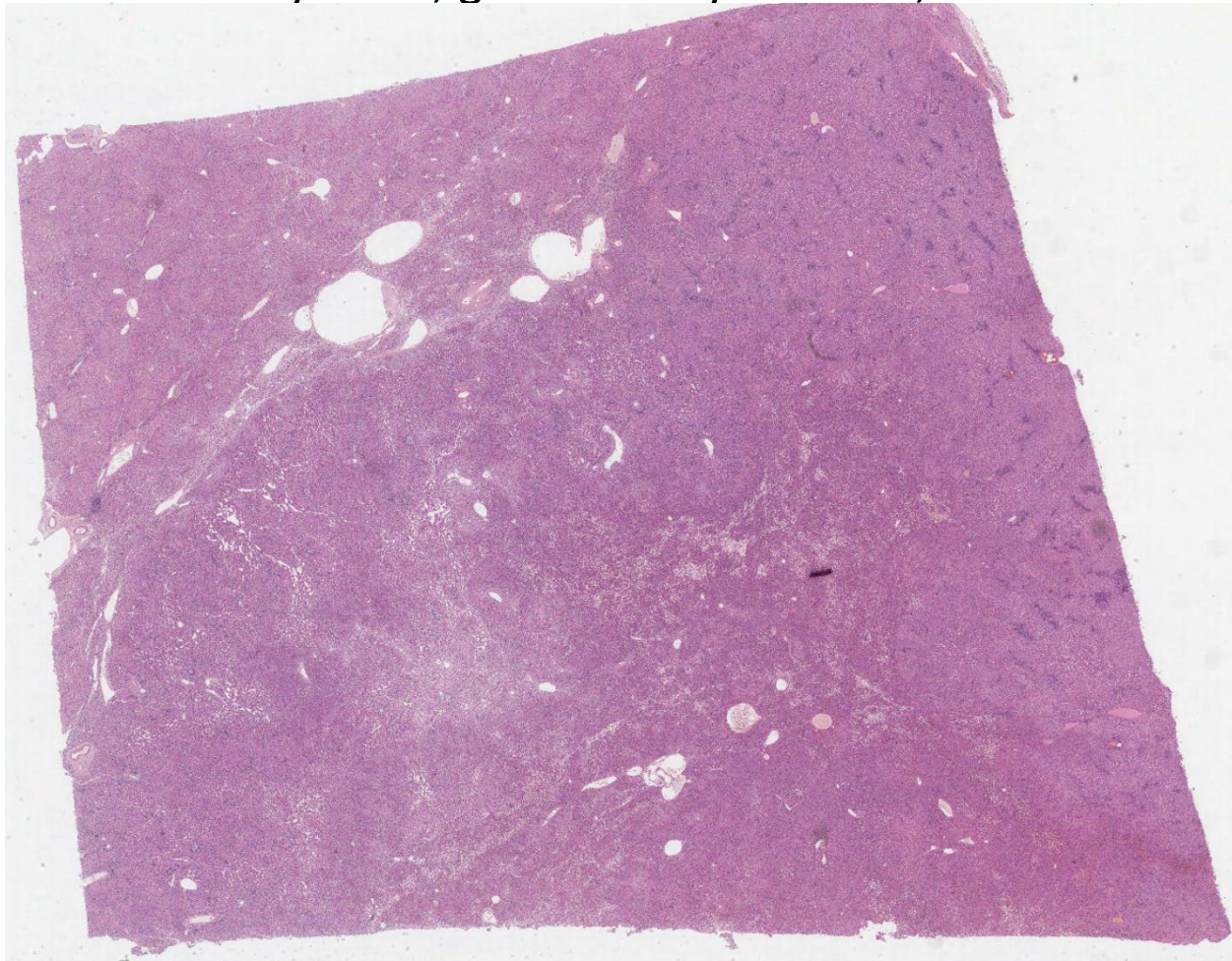


Case LS6 36 F

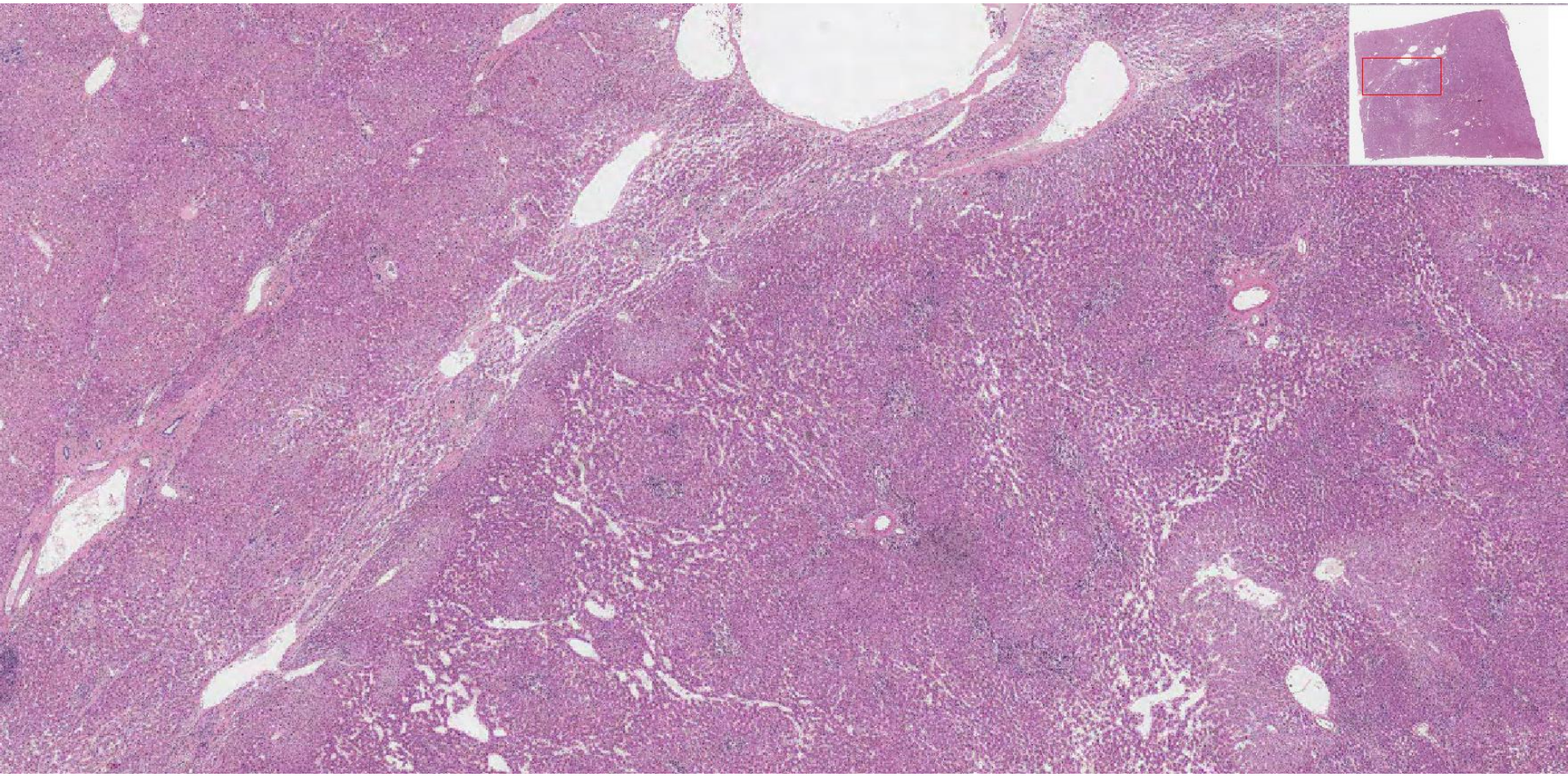
Turner syndrome. Focal liver lesion, ? Adenoma

Liver segments 6&7, contains a 50mm round tumour, slightly paler than surrounding liver.

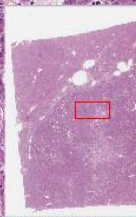
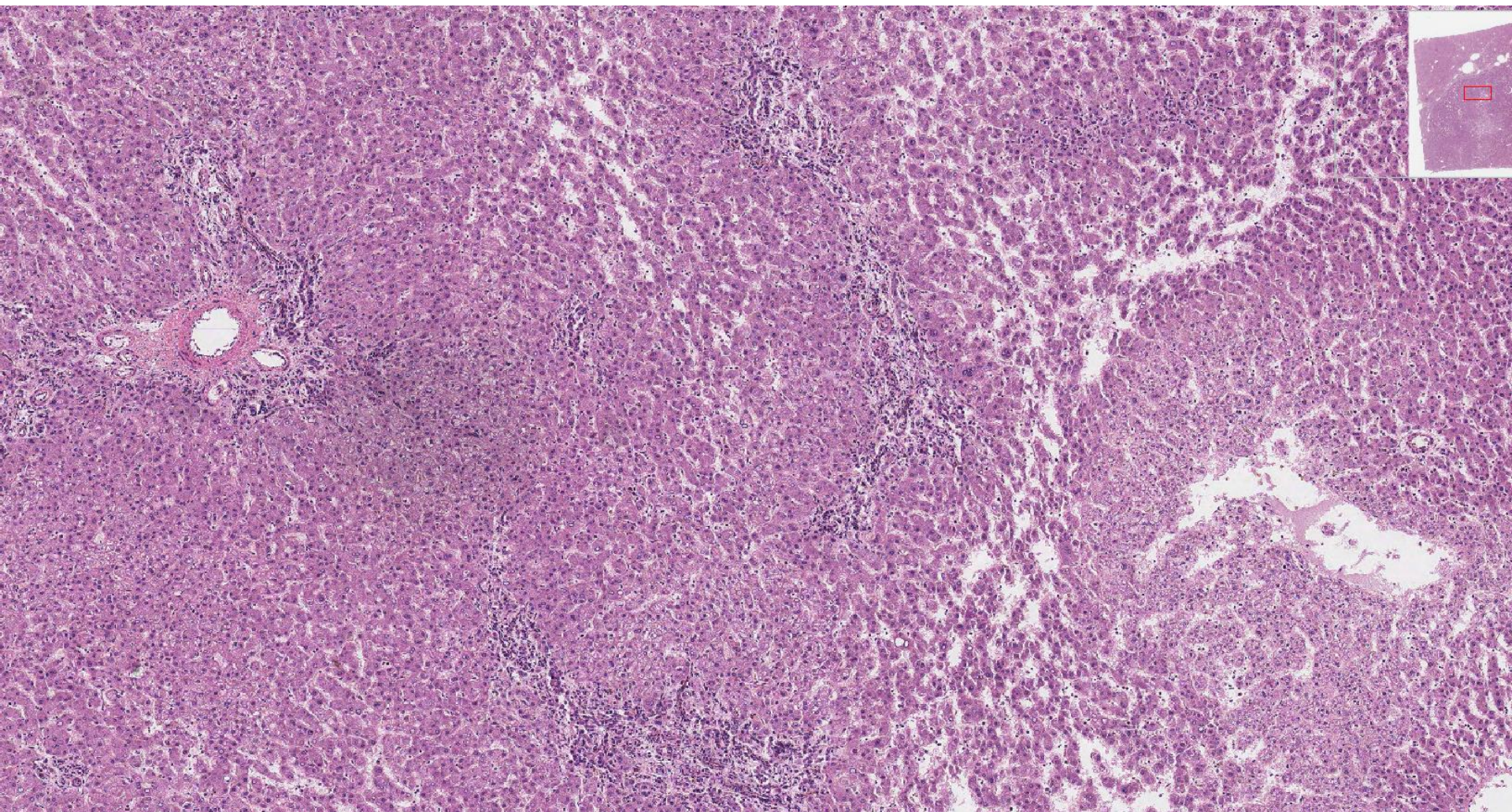
Also amyloid A, glutamine synthetase, beta catenin



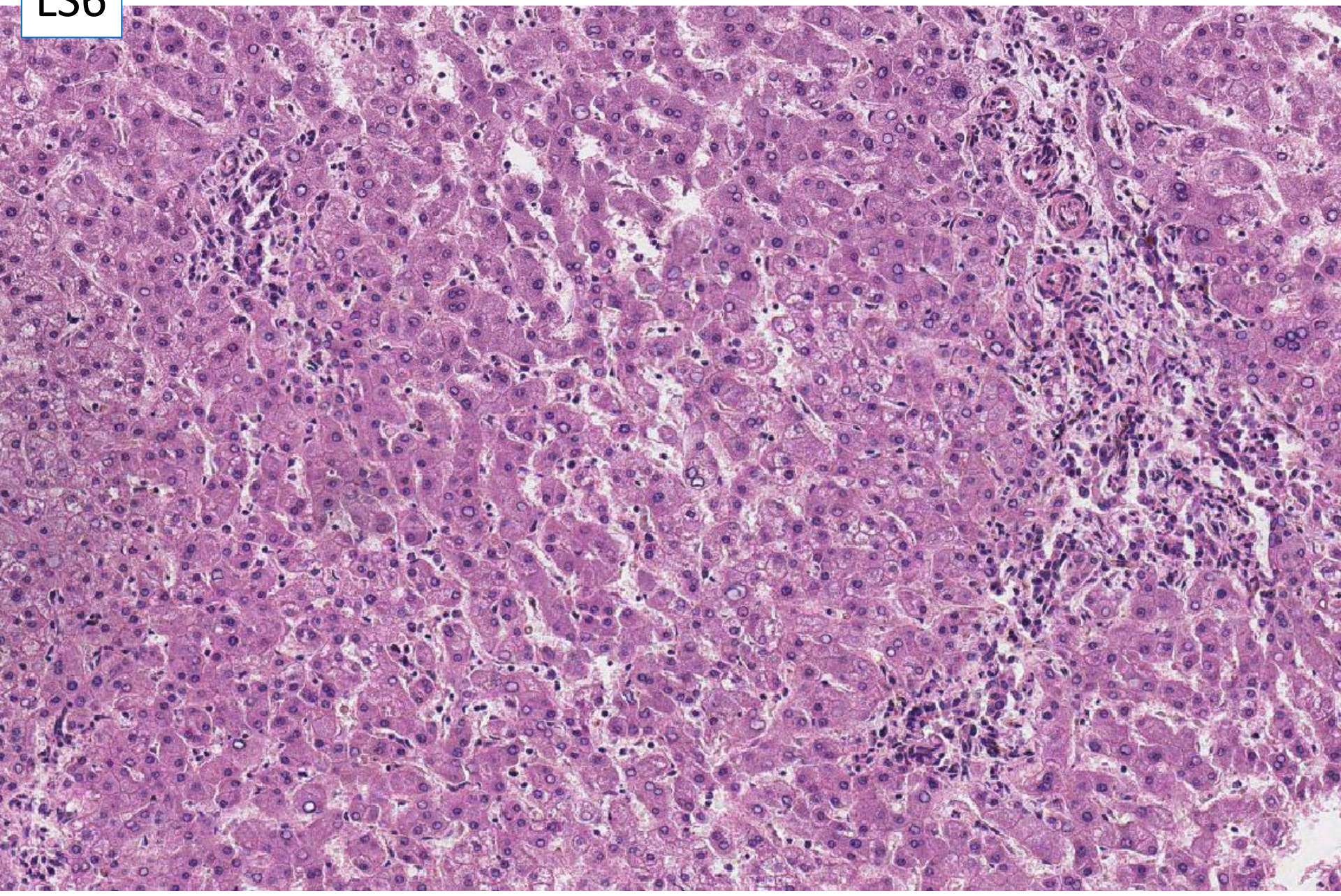
LS6



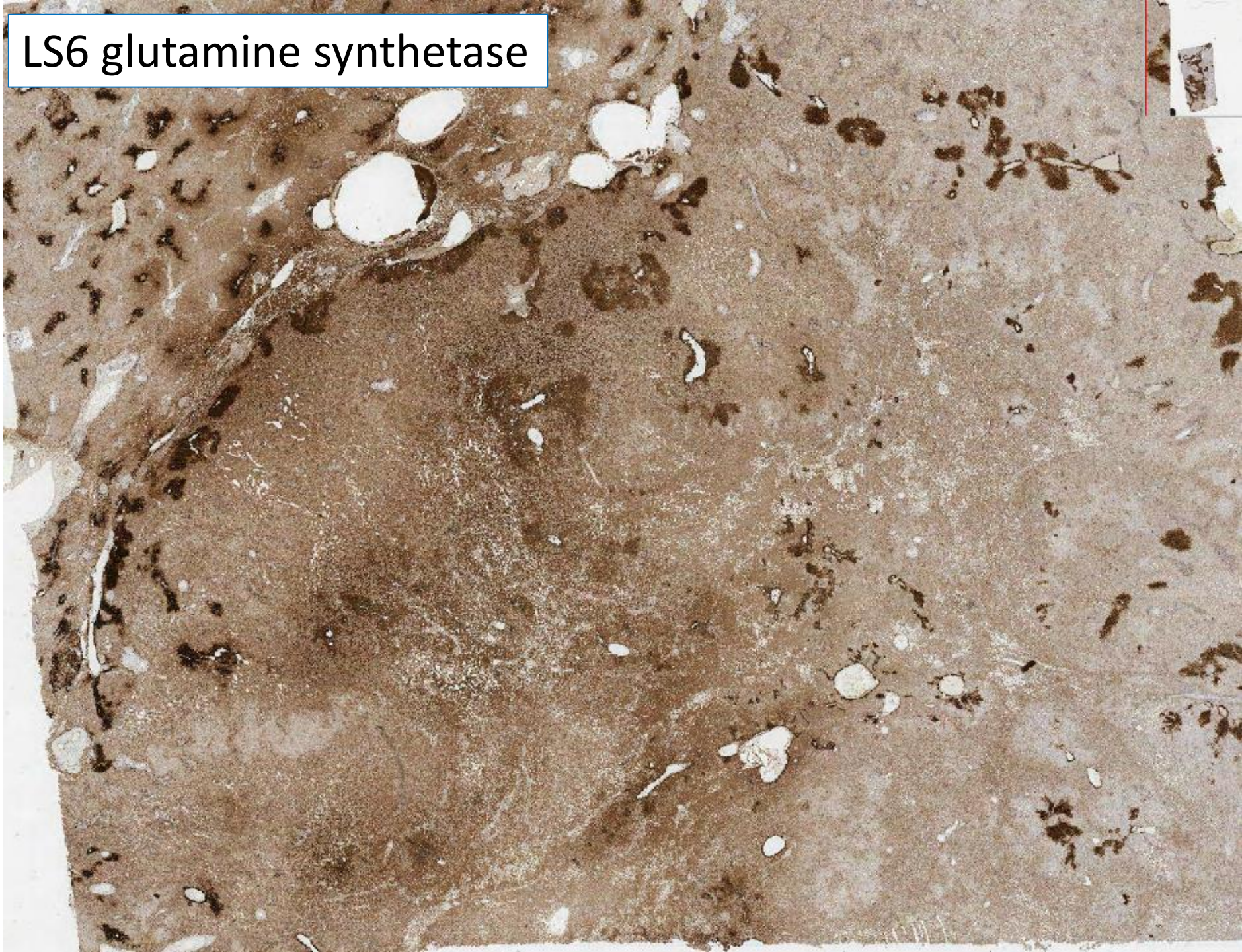
LS6



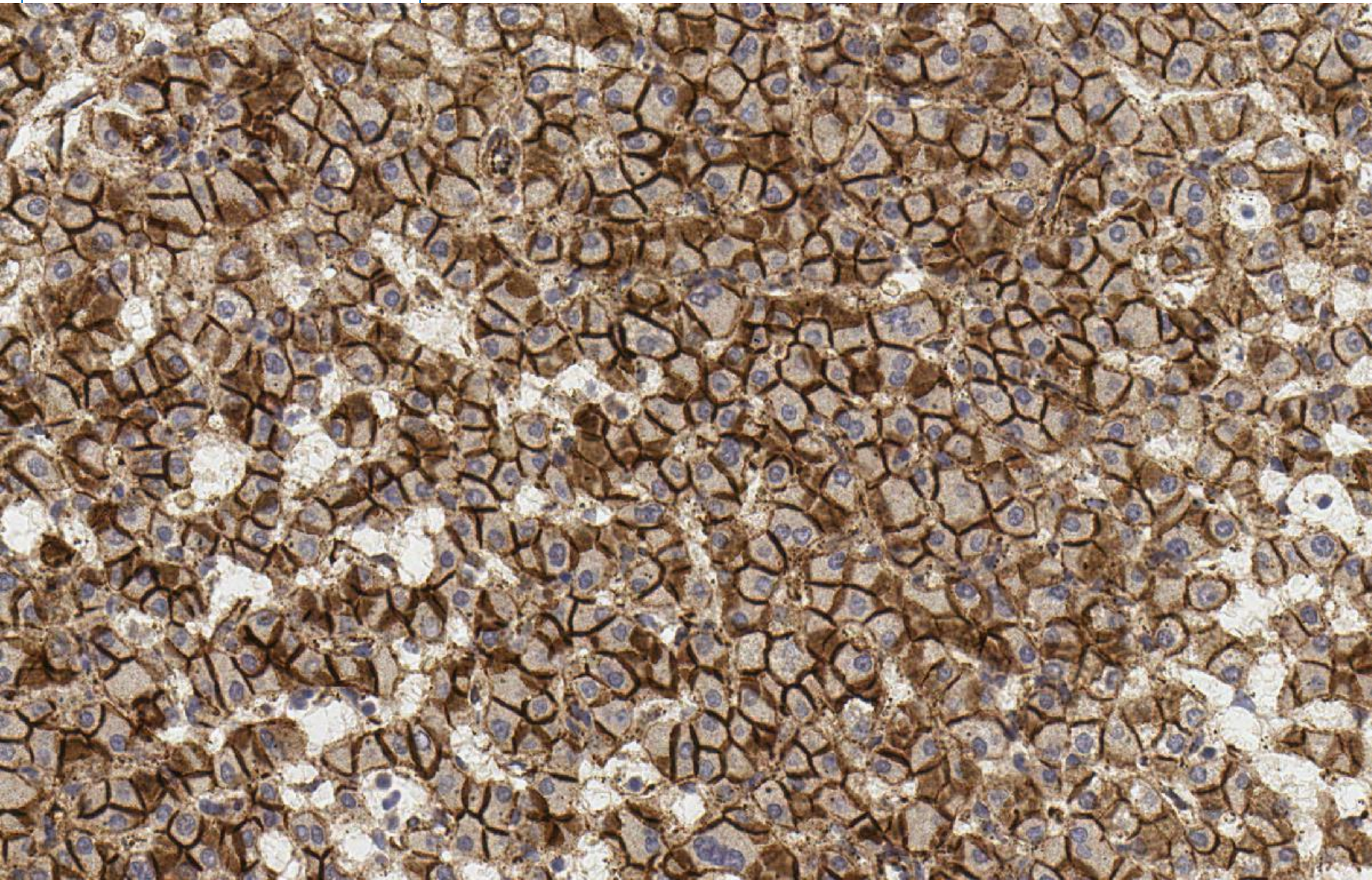
LS6



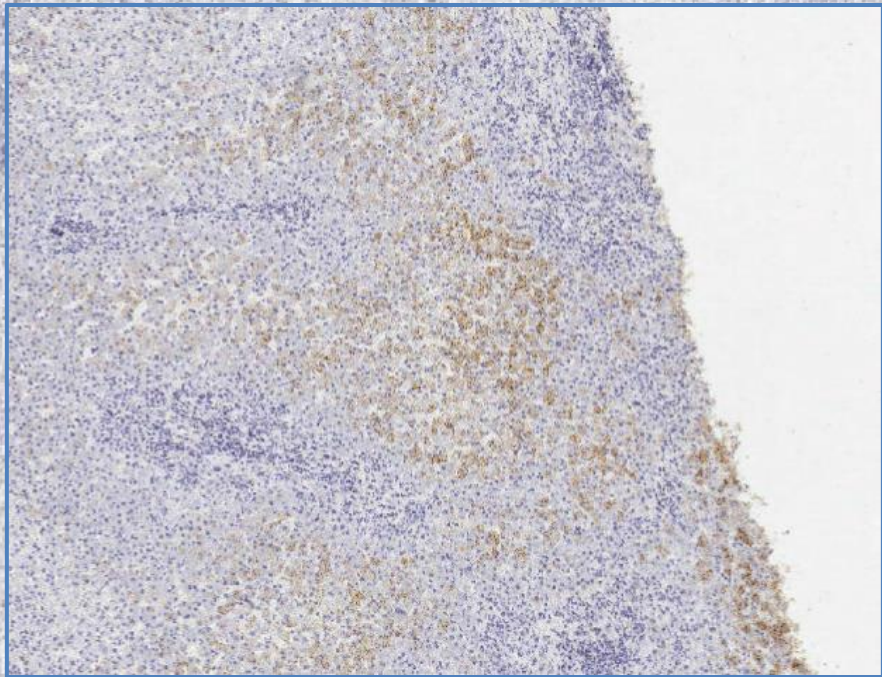
LS6 glutamine synthetase



LS6 beta catenin



LS6 serum amyloid A



Case LS6 36 F

Turner syndrome. Focal liver lesion, ? Adenoma

Liver segments 6&7, contains a 50mm round tumour, slightly paler than surrounding liver.

Also amyloid A, glutamine synthetase, beta catenin

A	Well differentiated hepatocellular carcinoma
B	Hamartoma
C	Focal nodular hyperplasia
D	Hepatocellular adenoma
E	Haemangioma